

Intraosseous Infusions: A Review for the Anesthesiologist with a Focus on Pediatric Use

Joseph D. Tobias, MD*†
Allison Kinder Ross, MD‡§

Intraosseous (IO) access is used most frequently for emergency care of critically ill infants and children when IV access cannot be rapidly achieved. Despite its efficacy in such situations, applications outside of the emergency room or resuscitation scenario have been limited. Furthermore, although the technique is emphasized in the teaching of those caring for critically ill infants and children in the emergency room or critical care setting, there is limited emphasis on its potential use in the perioperative setting. When peripheral venous access cannot be achieved in the operating room, alternative means of securing vascular access such as central line placement or surgical cutdown are generally successful; however, these techniques may be time consuming. Anyone providing anesthesia care for infants and children may want to become facile with the use of IO infusions for selected indications. We present the history of IO infusions, review the anatomy of the bone marrow space, discuss the potential role of IO infusions in the perioperative period, and analyze its adverse effect profile.

(*Anesth Analg* 2010;110:391-401)

The potential for the use of the intraosseous (IO) route for fluid resuscitation and the administration of medications was first entertained in 1922 by Drinker et al.¹ during pathologic examination of the marrow cavity of the sternum. This was followed by a report demonstrating the improvement in the clinical condition of 12 patients with pernicious anemia who received liver concentrate administered via the marrow cavity of the sternum.² In 1940, Tocantins and O'Neill³ described their experience with the IO administration of blood, saline solutions, and glucose to a cohort of 17 pediatric patients with only 1 failure. The IO route continued to gain popularity for the infusion of medications, antibiotics, blood, and other fluids particularly during situations of impossible venous access in children or as an alternative to infusion via the superior sagittal sinus in newborns.⁴⁻⁷ During this time, applications in the pediatric population transitioned to the tibia, the site used most frequently in today's practice, instead of the originally described site for the adult population, the sternum.

In 1947, Heinild et al.⁸ reported their experience with one of the largest series ever regarding IO infusions. They reported a success rate of more than

95% in nearly 1000 IO infusions in children ranging in age from 2 days to 4 yr. The majority of these patients required resuscitation because of dehydration from acute gastroenteritis. Given problems with IV access in that era, several of the patients received more than one IO infusion with one patient receiving 10. Various fluids and medications were infused through the IO needle including blood, plasma, and sodium bicarbonate. They were also the first to report the successful use of IO infusions in the treatment of preterm, low-birth-weight infants.

During the 1940s and 1950s, the IO route continued to be used during emergency situations in infants and young children in whom IV access could not be achieved. This time also saw the first development of specialized needles to penetrate the marrow cavity.^{9,10} Subsequently, the use of IO access decreased with advances in the techniques for central line placement, peripheral venous cutdown, and improvements in disposable plastic catheters, which improved the ease as well as the duration of peripheral IV access. In the 1980s, as there was increased focus in medical research and the literature regarding techniques for resuscitation and an increased recognition of the importance of early vascular access during lifesaving maneuvers, IO access was reintroduced to speed the obtainment of parenteral access in infants and children in various critical scenarios.¹¹⁻¹³

From the Departments of *Anesthesiology, and †Pediatrics, University of Missouri, Columbia, Missouri; and Departments of ‡Anesthesiology, and §Pediatrics, Duke University, Durham, North Carolina.

Accepted for publication August 27, 2009.

Address correspondence and reprint requests to Joseph D. Tobias, MD, Department of Anesthesiology, University of Missouri, 3W-27G HSC, One Hospital Dr., Columbia, MO 65212. Address e-mail to tobiasj@health.missouri.edu.

Copyright © 2010 International Anesthesia Research Society
DOI: 10.1213/ANE.0b013e3181c03c7f

PHYSIOLOGY OF THE IO ROUTE

The IO route provides access to the systemic venous circulation via the marrow or medullary cavity with its surrounding bone, which provides a noncollapsible entry point into the central venous circulation.

The medullary cavity of the long bones is composed of a network of venous sinusoids that are drained by a single central venous canal. These vessels do not collapse during shock, hypovolemia, or other critical illnesses. The central venous canal empties via the intramedullary or emissary vessels directly into the venous circulation. In the case of the tibial marrow space, the intramedullary vessel empties directly into the popliteal vein and then into the femoral vein. Although the rate of blood flow through the tibia varies based on the perfusion pressure, in experimental animals, flow has been measured at 15–50 mL/min.^{14,15}

Experimental and clinical studies have evaluated flow rates through bone marrow needles as well as the efficacy and onset time of various medications when administered via the IO route. Using 6 laboratory animals (calves) and a 13-gauge bone marrow needle, Shoor et al.¹⁵ recorded flow rates (mL/min) for normal saline of 10 ± 1 , 27 ± 2 , 32 ± 1 , and 41 ± 2 mL/min with gravity (81 cm above the heart), 100, 200, and 300 mm Hg pressure, respectively. No difference in these times was noted in 2 animals when they were phlebotomized to induce hypotension. Additional data regarding flow rates are available from actual clinical use. Tocantins et al.⁵ reported a gravity-driven flow rate via the proximal tibia or distal femur ranging from 0.5 to 4.3 mL/min (mean = 1.7 mL/min). Iserson and Criss¹⁶ anecdotally reported a similar maximum flow of 200 mL/h (3.3 mL/min) for crystalloid in a 9-kg pediatric patient.

Because the intramedullary vessel of the marrow space empties directly into the large central venous system, the onset times of medications administered via the IO route are comparable to those administered IV. There may be a somewhat prolonged duration of action of various medications with IO administration suggesting that the marrow cavity may act as a depot.¹⁷ Congo red, when injected into the tibia of a rabbit, can be detected in the right ventricle within 10 s.³ Prete et al.¹⁷ compared IV, IO, and endotracheal (ET) administration of atropine in 6 laboratory animals. IV administration resulted in higher plasma concentrations than IO administration at 0.75, 1.25, and 5 min, although statistical significance was achieved only at 0.75 min.¹⁷ At all points, IO administration resulted in higher plasma concentrations than ET administration and higher concentrations than IV administration at 5, 15, and 30 min. Papper¹⁸ demonstrated similar circulation times when comparing the antecubital vein and IO administration via the sternum in 7 adult patients. Equivalent changes in arterial blood pressure have been demonstrated when comparing the IV and IO administration of epinephrine.¹⁹ In the previously mentioned study of Shoor et al.,¹⁵ which evaluated flow rates with IO infusions, the authors also reported that the initial time to arterial blood pressure increase after the IO administration of epinephrine (0.5 mg) or ephedrine (50 mg) was 17 ± 3 s with 90% of the maximum effect achieved at 45 \pm

5 s. Berg²⁰ anecdotally reported the successful IO administration of a dobutamine and dopamine infusion in a 6-mo-old infant with septic shock.

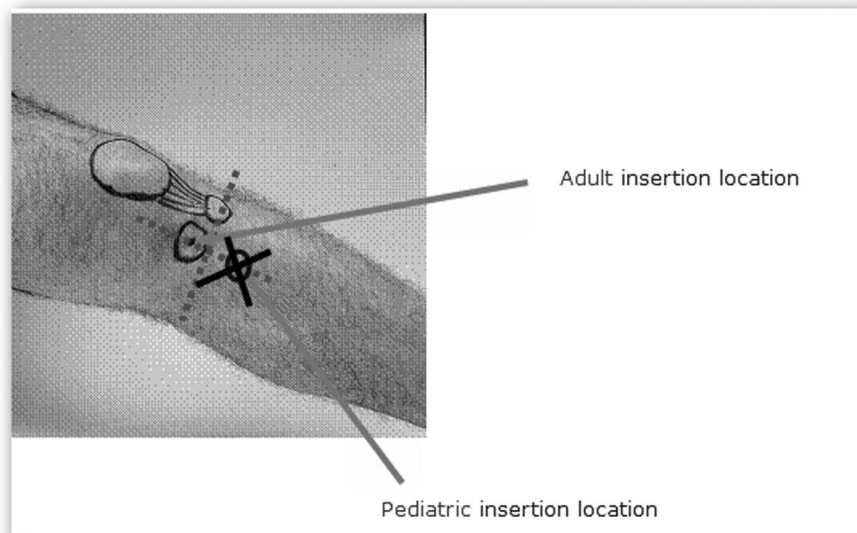
Orlowski et al.²¹ compared the pH increase after the IO or IV administration of sodium bicarbonate in a canine model. Although the average injection time was longer with IO administration (25 vs 15 s), there was no difference in the time to peak effect or the pH increase that was obtained. Spivey et al.²² reported similar results to those of Orlowski et al. in their comparison of the central IV, peripheral IV, or IO administration of sodium bicarbonate in a pig model during cardiopulmonary resuscitation. Similar effects were noted with the central IV or the IO administration of sodium bicarbonate, whereas peripheral IV administration was less effective.

Moore et al.²³ evaluated the time to respiratory arrest and loss of forefoot twitch in sheep after the administration of succinylcholine (1 mg/kg) via the IO, IV, and IM routes. The time to respiratory arrest was 30.8 ± 7.3 s with IV administration, 57.5 ± 10.3 s with IO administration, and 230 ± 106 s with IM administration. The time to ablation of the forefoot twitch was 93.3 ± 34.0 s with IV administration, 100.8 ± 24.2 s with IO administration, and 291 ± 109 s with IM administration. The authors concluded that the administration of succinylcholine via the IO route is comparable to IV administration and superior to IM administration. Anecdotal experience has demonstrated an onset time after IO administration of succinylcholine that is comparable to that achieved with IV administration in various clinical scenarios including shock, hypothermia, and increased intracranial pressure.^{24–27}

Spivey et al.²⁸ evaluated the efficacy of IV versus IO diazepam (0.1 mg/kg) in terminating pentylenetetrazol-induced seizure activity in an animal model. After the initiation of epileptogenic activity, 5 pigs were included in each of 3 groups including IV diazepam, IO diazepam, or control. One minute after IV administration of diazepam, the epileptogenic activity decreased to half of the control value and disappeared at 2 min. With IO administration, epileptogenic activity decreased to 10 s of activity per minute at 2 min and then disappeared at 8 min. In the control group, seizure activity had decreased to 50% at 8 min. Plasma diazepam concentrations peaked in both the IV and IO groups at 1 min with no difference in peak plasma concentrations. At 10, 15, and 20 min after administration, the values were higher with IO administration but did not reach statistical significance. The authors also mentioned their successful anecdotal experience with the termination of seizure activity with IO diazepam in an 18-mo-old child.

Kentner et al.²⁹ compared the IO and IV administration of hydroxyethyl starch (HES) in an animal model of resuscitation from hypovolemia. Mean arterial blood pressure was reduced to 40 mm Hg by phlebotomy from an arterial cannula over 30 min. After 30 min of hypovolemia, an IV or IO infusion of

Figure 1. Location on the tibia for the insertion routes for a pediatric or adult intraosseous infusion needle. (Reproduced with permission from WaisMed, Kansas City, MO.)



HES was administered ($10 \text{ mL} \cdot \text{kg}^{-1} \cdot \text{h}^{-1}$ for 30 min). There was no difference in the hemodynamic variables between the IO and IV groups. Both groups had a return of hemodynamic variables to baseline within 15 min of initiating the resuscitation. There was a similar increase in the plasma concentration of HES in the 2 groups (maximum of $5.82 \pm 0.44 \text{ mg/mL}$ in the IO group and $5.73 \pm 0.88 \text{ mg/mL}$ in the IV group). Because of the theoretical risk of bone marrow or fat emboli to the lungs (see below), the authors also monitored pulmonary vascular resistance as an indirect marker of pulmonary embolic events and noted no difference between the 2 groups.

TECHNIQUE OF IO ACCESS

In infants and children, the preferred site of access is the anteromedial surface of the tibia, approximately 1–2 cm below the tibial tuberosity (Fig. 1). At this point, the cortex is thinnest and therefore easiest to penetrate. It is generally agreed that this site can be used in children up to 6–8 yr old. Other reported sites for IO access have included the sternum, distal femur, lateral or medial malleoli, iliac crest, and even the distal radius. Although various needles and devices are currently available (see below), all that is necessary is a stylet needle of some type with some reports outlining the successful use of an 18- or 20-gauge spinal needle. For tibial placement, the tibial tuberosity is palpated and the medial aspect of the tibia approximately 1–2 cm below the tuberosity is identified. At this point, the tibia is relatively flat so that the bone can be stabilized and the needle is inserted at a 90° angle to the skin. Given that the patient is anesthetized or in extremis, topical or local anesthesia is generally not used, but infiltration of the skin and periosteum with 1% lidocaine should be considered for other situations. After sterile preparation of the skin, the needle is advanced using a back and forth rotating motion at a right angle to the bone until a loss

of resistance is felt as the cortex of the bone is penetrated. In smaller infants and children, excessive force may cause the needle to pass entirely through the bone and exit on the other side, a reason not to place the nondominant hand underneath the tibia for stabilization. This may be avoided by using a needle with a preset depth gauge on the shaft or one of the newer devices, which are described later in this article. Once the needle is seated in place, the stylet is removed and a 5-mL syringe is attached. At this point, the needle should stay in place without support. Traditionally, the confirmation of appropriate IO needle placement is determined by aspiration of blood or bone marrow and by free flow by gravity of crystalloid without evidence of extravasation. Even if marrow cannot be aspirated, the IO needle can be used if it flushes easily without extravasation and if there is free flow of fluid by gravity. Because the free flow by gravity may be slow, a 10-mL flush of saline can be administered after medications to speed their entry into the central circulation. Ultrasound has been reported as an alternative technique for confirmation, especially when a blood flashback cannot be ascertained. In a small pilot study using 8 cadavers, Stone et al.³⁰ reported that the sensitivity and specificity of ultrasound was 100%, whereas visual examination of the tubing drip chamber had a sensitivity and specificity of 88% and 25%, respectively.

NEEDLES FOR IO ACCESS

There are a variety of needles that have been used for IO access including butterfly needles, spinal needles, standard metal IV needles, and bone marrow biopsy needles. The use of needles without stylets may be problematic because there is a higher incidence of obstruction by bony spicules.² Given the demonstrated efficacy of this technique in resuscitative efforts, specialized IO needles (16 or 18 gauge) are manufactured by several companies. In addition to



Figure 2. Cook disposable intraosseous infusion needle with the Dieckmann modification and standard hub design (Cook Medical). Specialized intraosseous needle with circular handle to facilitate placement and stylet to prevent obstruction by bone spicules. When the circular handle with stylet is removed, the hub allows connection to standard IV tubing via the Luer lock. (Reproduced with permission from Cook Medical, Bloomington, IN.)

having stylets to prevent obstruction, these needles have specialized handles that help in their successful placement and short needle shafts to minimize the risk of dislodgement.

Using a pediatric cadaver leg, Iserson and Criss¹⁶ assessed the ease of use of various needles including 13-, 18-, and 20-gauge spinal needles, as well as standard metal IV needles. They found that the 13-gauge Kormed/Jamshidi (American Pharmaseal Laboratories, Glendale, CA) disposable bone marrow aspiration needle was the easiest to insert, did not become plugged with tissue during insertion, and was placed successfully on the first attempt. The spinal needles had a tendency to bend, whereas the standard hollow metal IV needles often became plugged because of lack of an obturator. Additionally, the authors reported that the small surface area around the hubs of the spinal needles and standard IV needles resulted in discomfort to the operator when twisting and pushing the needle in place.

In addition to the spinal needles, basic bone marrow biopsy and aspiration needles such as the SurFast (Cook Critical Care, Bloomington, IN) and the basic Jamshidi needle (Baxter Healthcare, Deerfield, IL) are considered manual devices that require the operator to exert manual pressure to penetrate the periosteum and enter the marrow cavity of the bone. Another frequently used manual device is the Cook Disposable Intraosseous Infusion Needle with the Dieckmann modification and standard hub design (Cook Medical, Bloomington, IN) (Fig. 2). All of these bone marrow biopsy and aspiration needles have the desired features as listed above that include a stylet and handle for ease of insertion.



Figure 3. EZ-IO device (Vidacare). (Reproduced with permission from Vidacare, San Antonio, TX.)

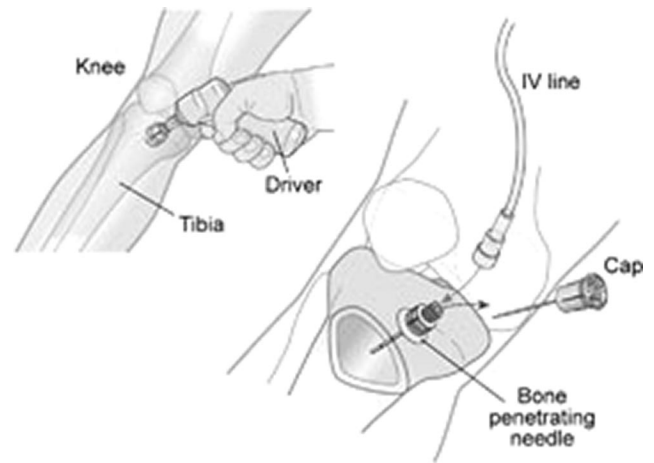


Figure 4. Demonstration on obtaining intraosseous access. Photo of EZ-IO device (Vidacare, San Antonio, TX).

Beyond manual devices, there are several products available that have simplified the insertion of an IO needle as they are not dependent on the manual process. The EZ-IO (Vidacare, San Antonio, TX) is a reusable lithium battery-powered device that is shaped and operates very much like a small drill (Fig. 3). The driver itself is a sealed unit with 8 AA lithium batteries that is marketed as being good for 700 insertions. It uses a beveled drill tip that rotates into the IO space at a preset depth. The needle is 15 gauge and there are 3 needle lengths (15 mm for children weighing 3–39 kg, 25 mm for patients weighing ≥ 40 kg, and a new 45-mm length for patients with significant tissue or edema overlying the bone). Once the needle enters the IO space by the drilling motion, which is noted by a loss of resistance, the stylet is withdrawn and a metal catheter remains with a Luer lock attachment left in place (Fig. 4). Insertion into the intramedullary space is confirmed by visualizing a flash of blood and aspiration is not necessary. A connection system (EZ-Connect) comes with each needle set and a 90° low-profile extension for delivery of medications and/or fluids; however, it is recommended by the manufacturer that the catheter be removed within 24 h. Sites that have been cleared by the Food and Drug Administration for the EZ-IO device are the proximal tibia, distal tibia, and proximal humerus.



Figure 5. Pediatric version of the Bone Injection Gun (B.I.G.) (WaisMed). (Reproduced with permission from WaisMed, Kansas City, MO.)

The Bone Injection Gun (B.I.G., WaisMed, Kansas City, MO), introduced in 2000, was the first automatic IO device. The gun is positioned 90° to the skin and held firmly with 1 hand while the other hand pulls out the safety latch. The B.I.G. then uses a “position and press” mechanism with a spring-loaded device that actively penetrates the cortex when a button is pushed (Fig. 5). Beyond simply applying the B.I.G. firmly against the skin, no additional force is needed before triggering the device. Once the IO space is penetrated, the device is removed, and a safety latch slides over the needle to keep it securely placed before taping.

The B.I.G. device is available in sizes that allow use from neonate to adult. The manufacturer’s recommended primary injection site for the B.I.G. in infants and children aged 0–6 yr is 0.5 in. medial and distal to the tibial tuberosity. In children aged 6–12 yr, the measurement is 0.5–1 in. medially and distally from the tibial tuberosity. The red-colored B.I.G. for this younger age group uses an 18-gauge needle and has numbers on the barrel of the device that correlate to the age of the patient. The operator should dial to the appropriate patient age to select the proper needle depth upon injection. The device, like all IO devices, should be directed away from the epiphyseal plate or joint capsule. For adults, the B.I.G. is blue in color and a 15-gauge needle is used. Unlike in children, the recommended insertion site for adults is 1 in. medial and 0.5 in. proximal to the tibial tuberosity.

In addition to the devices that are designed to enter the marrow cavity of the tibia, there is a device (the FAST1® [First Access for Shock and Trauma], PYNG Medical, Vancouver, BC, Canada) that is specifically designed for sternal use in adults but has been approved in adolescents down to 12 yr of age. The FAST1 consists of a set of needles, catheters, and stabilizer points that determine or measure the depth from the skin surface to the periosteum of the sternum



Figure 6. First Access for Shock and Trauma Device (FAST1®). (Reproduced with permission from PYNG Medical, Vancouver, BC, Canada.)

(Fig. 6). A patented patch that exactly demonstrates the correct area for placement of the FAST1 device is applied to the patient’s manubrium after the sternal notch is identified. Once the patch identifies the area for insertion, user-operated 60 psi is manually applied to the device while the stabilizer points secure the location and a central needle injects a plastic catheter through the cortex into the medullary space of the bone to a depth of 6 mm. The entire device is then withdrawn while the plastic catheter remains, and a plastic dome is placed as a protective covering. The advantage of the FAST1 is the more rapid delivery of medications and fluid directly into the central circulation compared with other IO sites. Maximum time for catheter use is 24 h (Table 1).

When considering use of IO devices in the pediatric population, bone marrow biopsy needles for manual insertion are available in 16- and 18-gauge sizes for various size infants and children, whereas the EZ-IO and B.I.G. devices also provide needles of appropriate size and depth for use in the pediatric population. This is not true for the sternal access device, FAST1, which is currently available only in an adult size with a pediatric device in the development phase (personal communication with PYNG medical representative).

Calkins et al.³¹ compared 4 different systems for IO placement including the FAST1, the B.I.G., a hand-driven threaded-needle SurFast (SF, Cook Critical Care), and the straight Jamshidi needle (Baxter Allergiance, McGaw Park, IL). They found that all 4 systems were easy to learn to use and provided secure access. The B.I.G. was successful in 29 of 31 insertions with a placement time of 70 ± 33 s. The SurFast was successful in 30 of 31 insertions with a placement time of 88 ± 33 s but had the highest extravasation rate. The Jamshidi needle was also successful in 30 of 31 placements with a placement time of 90 ± 59 s. However, the flow was noted to be slow in 7 of the 30 successful placements. The FAST1 was successful in 29 of 31 insertions; however, the mean placement

Table 1. Comparison of Intraosseous Devices

Device	Summary of features	Recommended ages for use	Sizes available	Advantages
Butterfly needles	Simple needle design	All ages	Variety of lengths and gauges	Variety of sizes are readily available
Spinal needles	Straight needle with stylet	All ages	Variety of lengths and gauges	Variety of sizes are readily available
Bone marrow biopsy needles	Hand-held hollow needle with stylet and handle	All ages	16- and 18-gauge needles. Various lengths	Variety of sizes are readily available
EZ-IO	Lithium-powered drill leaving metal catheter in place	All ages down to 3 kg	15-gauge needles. Length 25 mm (>40 kg) and 15 mm (<40 kg)	Automatic, easy to operate, preset depth obtained depending on needle size used
Bone Injection Gun (B.I.G.)	Spring-loaded device using "position and press" action	All ages	18-gauge (<12 yr) and 15-gauge needles (>12 yr). Variable lengths	Automatic, easy to operate
FAST1®	Sternal needle device that inserts plastic catheter	Adults down to age 12 yr, but no pediatric device at present		Automatic, easy to operate, easily secured plastic catheter, rapid delivery of medications and fluids

time was significantly longer than the other 3 devices (114 ± 36 s).

When comparing the traditional manual method using a Jamshidi needle with the automatic B.I.G., there was a faster time to placement of the IO device in the B.I.G. group (16.91 vs 11.93 s).³² Although statistically different, both devices were placed in a timely fashion and with similar ease-of-use ratings among the Emergency Medical Technician students and practicing paramedics. Similar results were reported by Brenner et al.³³ when comparing manual IO infusion devices versus the EZ-IO in adult human cadavers. Although insertion times were similar, access was achieved more successfully on the first attempt when using the EZ-IO (97.8% vs 79.5%). User ease was scored higher in the automatic device and there were fewer technical complications when compared with the manual technique (0% in EZ-IO group vs 15.4% with the manual device). When compared with the results of Calkins et al., insertion times for both of these comparison studies were considerably shorter.

In adult trauma patients, insertion success rates were compared between the FAST1 and EZ-IO devices.³⁴ This field trial included a training session with hands-on instruction for emergency service personnel before the use of the 2 devices. The field trial of the FAST1 occurred first, followed by the trial for the EZ-IO device. There was immediate feedback regarding the use of the devices upon insertion in the field. One hundred seventy-eight insertions were evenly divided between the FAST1 and EZ-IO. The success rate of device insertion was 64 of 89 (72%) with the FAST1 and 78 of 89 (87%) with the EZ-IO, although there was no difference between the 2 devices with respect to first attempt success rate. Provider comfort was similar for each model and there was no difference in device effectiveness with regard to infusion.

Failures for each model were attributed to excessive tissue over the insertion site, inability to infuse, and fluid extravasation around the insertion site. These failures led the study personnel to recommend a device with a longer needle for the bariatric population. In addition, with the FAST1, there were problems with the catheter dislodging or breaking that were best avoided when proper technique with linear alignment of the elbow and wrist occurred during insertion to avoid torque. Difficulties with the EZ-IO included loss of drill power with insertion, most likely caused by the drill being pushed against the bone with too much force to allow the drill to have adequate rotation speed to penetrate the bone. The majority of the providers also thought that the drill was underpowered, a problem that can be alleviated by using a lithium ion battery pack rather than regular AA batteries.

REPORTS OF INTRAOPERATIVE AND IN-HOSPITAL IO USE

Although used most frequently in prehospital or emergency room scenarios, IO access has been anecdotally reported in both the inpatient and intraoperative care of pediatric patients. Harte et al.¹¹ used IO access in an 11-mo-old girl who had presented with multiple organ injuries secondary to a motor vehicle accident. During the course of a lengthy stay in the pediatric intensive care unit (ICU), she had multiple peripheral venipunctures, bilateral femoral and brachial central venous catheters, bilateral saphenous vein cutdowns, and a right internal jugular venous line. Although she was eventually transferred out of the ICU, a cardiopulmonary arrest occurred, requiring reestablishment of vascular access. When attempts to reestablish peripheral and central venous access

failed, bilateral tibial IO catheters were placed and used for successful resuscitation with the administration of sodium bicarbonate, calcium chloride, epinephrine, and dopamine.

Similar success was reported by Lake and Emmerston³⁵ with the use of IO access in an inpatient, former preterm infant of 25 wk gestation who had been hospitalized for several weeks and subsequently developed acute deterioration after the removal of previously placed percutaneous and central venous catheters. An 18-gauge butterfly needle was used to gain IO access via the infant's left tibia thereby allowing for the emergent infusion of fluids, antibiotics, sympathomimetic drugs, and analgesia.

As early as 1952, Tarrow et al.³⁶ recognized that the IO route was plausible for the induction and maintenance of anesthesia noting that "the agents used in anesthesia may be given by way of the bone marrow with as rapid an effect as when given IV." Additionally, reports from the veterinary literature demonstrate the efficacy of the IO route for the induction of anesthesia in various animal species.^{37,38} Valcerde et al.³⁷ demonstrated the effective induction of anesthesia with either ketamine or thiopental in chickens and additionally demonstrated a lack of histopathologic changes in the bone marrow related to these medications. Kamiloglu et al.³⁸ compared the effects of IM and IO ketamine in domestic pigeons. The onset of anesthetic effect was more rapid with IO as compared with IM administration (1.8 ± 0.4 min vs 7.5 ± 0.8 min).

There are a limited number of reports regarding the use of IO access in the operating room setting.³⁹⁻⁴¹ In 3 of these cases, the IO route was used in a nonemergent situation when there were difficulties with obtaining vascular access. Stewart and Kain³⁹ used the IO route in a 3-mo-old, low-birth-weight infant with polycythemia secondary to cyanotic congenital heart disease and a long history of difficult venous access when anesthetic care was required for revision of a ventriculoperitoneal shunt. Comorbid features included previous long-term use of percutaneous central venous access, prior venous cutdowns in all 4 extremities, and approximately 200 peripheral venipuncture attempts during a 12-wk stay in the pediatric ICU. After the inhaled induction of anesthesia, the decision to use the IO route was made after 20 min of unsuccessful attempts at peripheral IV placement. After successful establishment of IO access, pancuronium was administered. The IO access was discontinued after the scheduled surgery and no complications were noted.

Boucek and El Magd⁴⁰ described their planned approach of combining IO, intrarterial, and surgically fashioned venous sites in a 52-yr-old woman scheduled for multivisceral transplantation. Because of an extended period of parenteral nutrition administration, venous access was eventually maintained via lumbar and transhepatic catheters that were placed

using radiological guidance. Bilateral occlusion of the brachiocephalic, superior vena cava, and iliac veins was present on radiologic imaging studies. Attempts to recannulate these central veins were unsuccessful and during one attempt, the atrial appendage was avulsed from the superior vena cava. At the time of the planned transplantation surgery, the patient's only patent venous access was a small-bore transhepatic catheter. This catheter was used for the IV induction of anesthesia. IO access was planned preoperatively as part of their approach to this patient and access was obtained in the patient's right tibia using a 15.5-gauge IO infusion needle. However, flow was deemed inadequate for rapid transfusion and, although the needle was left in place to avoid periosteal bleeding, it was not used for intraoperative fluid administration. Intraoperatively under direct vision, acceptable venous access was obtained via the inferior mesenteric and ovarian veins.

Joshi and Tobias⁴¹ reported the successful use of IO access in an 8-mo-old, 5.4-kg infant with cyanotic congenital heart disease who was scheduled for direct laryngoscopy. During a prolonged illness in the pediatric ICU, which required chronic mechanical ventilation, the patient had several peripheral and central venous catheters placed. Because of the thrombotic disease of the superior and inferior vena caval systems, the patient's last central venous catheter, which had become nonfunctional 1 wk before the surgical procedure, was placed via a translumbar approach under radiologic guidance. When peripheral IV access could not be obtained, an 18-gauge IO needle was inserted into the right tibia. Ampicillin (50 mg/kg) was administered for subacute bacterial endocarditis prophylaxis. Atropine (5 μ g/kg) was administered via the IO needle and the sevoflurane concentration was increased to 6% to allow for the performance of the direct laryngoscopy and bronchoscopy with assisted ventilation. Two IO doses of propofol (1 mg/kg) were administered during the direct laryngoscopy to achieve a deeper plane of anesthesia. After completion of the airway examination, which required 15 min, the infant was transported to the pediatric ICU with the IO needle in place. Once the infant had recovered from the general anesthetic, tube feedings were restarted. When the tube feedings were tolerated without incident for 3-4 h, the IO needle was removed. Before its removal, vancomycin (10 mg/kg) was administered. The remainder of the postoperative course was uneventful.

In a final intraoperative report, Waisman et al.⁴² described the use of IO access to provide IO regional anesthesia as an alternative to IV regional anesthesia (Bier block). Preliminary work was performed in 5 dogs and in a cadaver model to demonstrate the feasibility of the technique and determine the best site for access. The most effective sites for access of the upper extremity were the distal radial metaphysis or epiphysis and the distal ulna epiphysis for the upper

extremity. For the lower extremity, the best sites were found to be the proximal tibial epiphysis or metaphysis, the medial malleolus, and the distal epiphysis of the first metatarsus. They then demonstrated the efficacy of the technique for providing intraoperative anesthesia in 106 of 109 patients. Lidocaine levels were acceptable after tourniquet release.

Clearly, the use of IO access is not considered first line for intraoperative management in elective procedures. Particularly when a child will require IV access postoperatively for any extended period, the benefits for intravascular lines will outweigh those of IO access. However, it should be part of an algorithm that includes numbers of attempts at peripheral access, time taken at attempts at peripheral access, feasibility of central access, and other factors including the need for continued postoperative access to guide the decision. There is no such algorithm for elective procedures because the mindset remains that the IO route is for emergency situations.

COMPLICATIONS OF AND CONTRAINDICATIONS TO IO ACCESS

As with any invasive procedure, complications may occur with the use of IO access. A 1990 review of the literature reports that IO catheters cannot be placed 20% of the time because of operator failure to use appropriate landmarks, bending of the needle, dense marrow within a small cavity, or replacement of marrow by fat or fibrous tissue.⁴³ Administration of hypertonic or strongly alkaline agents has been associated with an increased incidence of local infection, transient medullary histologic changes, and myonecrosis in animal models.^{43,44} Heinild et al.⁸ concluded that, among pediatric patients, hypertonic solutions were associated with an increased incidence of osteomyelitis when compared with patients receiving blood transfusions or isotonic fluid infusions. These issues have led to the suggestion that hypertonic solutions should be diluted before IO administration. Technical complications of the IO route include the possibility of needle dislodgement resulting in extravasation of fluid and medications resulting in tissue damage or even compartment syndrome.⁴⁵

Other potential complications include iatrogenic fracture, infectious complications, growth or epiphyseal plate injury with subsequent leg length discrepancy, and fat embolism. Using an animal model (piglets with an average weight of 30.9 kg), Hasan et al.⁴⁶ evaluated the impact of the amount of fluid administered, the pressure used to deliver the fluid, and the rate of administration on fat embolization. A bolus of 20 mL/kg fluid was administered under 300 mm Hg pressure in Group 1 ($n = 6$), 20 mL/kg fluid was administered under gravity flow in Group 2 ($n = 6$), 100 mL of fluid was administered over 20 min in Group 3 ($n = 8$), and 100 mL of fluid was administered over 7 min in Group 4 ($n = 8$). Lung specimens from

both upper and lower lobes were subsequently examined. Fat emboli (1–3 per high-power field) were found in approximately 30% of the lung samples with no statistically significant difference among the 4 groups. Orłowski et al.⁴⁷ also demonstrated as many as 4.48 fat emboli per square millimeter of lung tissue after IO infusions in a canine model. However, when evaluating changes in arterial blood gases to assess ventilation-perfusion relationships, there was no clinical effect noted related to the fat emboli. Despite these animal studies, there have been no documented cases of either fat or cortical bone emboli after IO infusions in infants and children. However, the literature continues to suggest that this may be a real complication of IO infusion in adults because of the differences in composition of the marrow cavity when comparing children with adults.⁴⁸ Before 5 yr of age, the intramedullary space of the bone is predominantly composed of red marrow. After 5 yr of age, a significant portion of the red marrow has been converted to the less vascular, yellow marrow, which has a much higher fat component. These changes result in more difficult access, decreased infusion rates, and a potentially increased risk for fat emboli. However, in a prospective nonrandomized trial that included 50 adults, fat embolism was not among the complications noted.⁴⁸

Rosetti et al.¹³ reviewed 30 clinical studies involving 4359 attempted IO infusions in pediatric and adult patients. Osteomyelitis occurred in 27 patients or an incidence of 0.6%. A single infusion lasting <1 h resulted in a similar risk of osteomyelitis when compared with a longer, continuous infusion. The authors recommended that hypertonic and alkaline fluids or medications be avoided or diluted. They also stressed the importance of maintaining appropriate sterile technique to limit the incidence of osteomyelitis. Antibiotic coverage for staphylococcal infection may be used if compromise of sterile technique is suspected.

Bowley et al.⁴⁹ described an iatrogenic fracture associated with IO access in a 2-yr-old trauma patient after IO access placement was attempted unsuccessfully with an 18-gauge B.I.G. device at the left proximal tibia followed by 2 manual attempts with the same needle at the same site. The authors reported that “considerable force was required” by the 100-kg emergency room physician. Once the device was inserted, a 20 mL/kg bolus of crystalloid was started and completed without difficulty. A full skeletal survey later revealed a fracture of the proximal tibia, which was deemed to be iatrogenic, despite the multiple traumatic fractures found elsewhere. Given this albeit rare complication, it has been suggested that follow-up radiographs be obtained for all children in whom IO access has been attempted.^{49,50}

Multiple attempts to gain access at the same site are discouraged because repeated long bone puncture attempts can result in extravasation of subsequently

Table 2. Comparison of Complications of Intravascular Routes

	Potential complications or disadvantages
Cutdown access	Infection Requires proper supplies/operator Limited utility in true emergency
Central line access	Pneumothorax Hemothorax Infection Ventricular arrhythmias Arterial puncture or hematoma
Intraosseous access	Extravasation from dislodgement Iatrogenic fracture Growth plate injury Infection Osteomyelitis

administered resuscitation drugs, leading to skin necrosis or compartment syndrome. Despite concerns expressed regarding damage to the growth plate, there are no reports of such injuries. In a prospective follow-up of tibial length after IO infusion in 10 pediatric patients, Fiser et al.⁵¹ found no identifiable growth disturbance at 1 yr. The greatest difference was 0.6 cm in 2 of the patients, 1 of whom had a longer tibia on the side of the infusion, whereas the other had a longer control tibia. Heinild et al.⁸ roentgenographically examined 72 of the 495 patients in their study over the course of 1–2 yr and concluded that IO blood transfusion at the tibial site may result in transient radiologic changes, but these changes are not permanent and did not appear to affect bone growth.

There are few absolute contraindications to IO placement. These include bone diseases, such as osteogenesis imperfecta, osteopetrosis, or other disorders with an increased incidence of fracture, infection or thermal injury to the overlying skin, or the presence of a fracture. Previously used sites for IO access should not be used for 1–2 days and repeated attempts at the same site are discouraged. An additional concern when IO access is used intraoperatively is that the IO site may be difficult to secure and maintain in place, especially in the operating room setting, thereby leading to potential malfunction at a critical time during anesthetic management. Manufacturers have responded to this concern by providing devices that include the equipment and instructions on how to secure the IO line once inserted.

Complications of the IO route are compared with other intravascular routes in Table 2. Although all routes include infection as a potential complication, the length of time that the access is kept in place is more predictive of infection rate than the actual route of access itself.

CONCLUSION

When vascular access cannot be obtained intraoperatively, there are various options including percutaneous

placement of a central venous cannula, achieving peripheral venous or central venous access via a cutdown, use of the IM route, or placement of an IO needle. Because each of these techniques has its own advantages and disadvantages, the appropriate choice must be based on the risk/benefit ratio given the clinical scenario. Intravenous access remains the route of choice, but may in rare cases be unattainable, both at alternative peripheral sites (scalp, chest wall, and abdominal wall veins) and at central venous sites despite multiple attempts by experienced hands. Venous cutdown may not be practical in emergent situations because of inherent time constraints. Cutdown access is achieved at approximately 11 min for neonates, 8 min in patients 1 mo to 5 yr of age, and 6 min in patients older than 6 yr.⁵² Although certain drugs may be administered via the IM route, such as succinylcholine, rocuronium, and atropine, there may be variability in absorption depending on the site of injection and the hemodynamic status of the patient, thus resulting in an unpredictable or delayed onset time.⁵³ The IM route is not feasible for many other medications and also cannot be used for fluid resuscitation. With respect to ET intubation using a deep plane of inhaled anesthesia, complications may be more likely when ET intubation in infants is performed without the use of neuromuscular blocking drugs.⁵⁴ Except for very brief procedures, vascular access is still required as there are a limited number of medications that can be administered via the ET tube and these are used only during resuscitative efforts. Additionally, in infants with comorbid features such as congenital heart disease, establishment of vascular access before ET intubation is often preferred because a deep plane of inhaled anesthesia may result in hemodynamic instability.

The current applications of IO access primarily include the emergent resuscitation of infants and children when IV access cannot be obtained in emergent scenarios including cardiac arrest, traumatic and thermal injuries, shock, status epilepticus, and diabetic ketoacidosis. In these clinical scenarios, IO access has been used for the administration of fluids and vasoactive medications. In addition to isotonic crystalloid, the IO route has been used for the administration of various blood products (fresh frozen plasma, whole blood, and packed red blood cells). Medications administered have included epinephrine, dopamine, dobutamine, digitalis, diazoxide, calcium, diazepam, phenytoin, antibiotics, insulin, glucose, heparin, and neuromuscular blocking drugs including succinylcholine. Current resuscitation guidelines suggest that the IO route should not be used as a routine alternative to venous access but rather should be limited to situations in which peripheral and central vein cannulation cannot be rapidly obtained.^{55–57} Although rarely reported in the anesthesia literature, it seems that IO access is a technique that anyone involved in the

provision of anesthesia care to children should consider when presented with the infant or child who has difficult IV access. In emergency situations, it can be used for the administration of lifesaving medications and may on occasion be used when other attempts at venous access fail. With appropriate technique and equipment, the literature reports an acceptably low complication rate. Given that IO access may be occasionally used in the perioperative setting in both emergent and nonemergent scenarios, it may be beneficial to have appropriate IO needles in the operating room.

REFERENCES

1. Drinker CK, Drinker KR, Lund CC. The circulation in the mammalian bone marrow. *Am J Physiol* 1922;62:1-92
2. Josefson A. A new method of treatment—intraosseous injection. *Acta Med Scand* 1934;81:550-4
3. Tocantins LM, O'Neill JF. Infusion of blood and other fluids into the circulation via the bone marrow. *Proc Soc Exp Biol Med* 1940;45:782-3
4. Tocantins LM, O'Neill JF. Infusion of blood and other fluids into the general circulation via the bone marrow. *Surg Gynecol Obstet* 1941;73:281-7
5. Tocantins LM, O'Neill JF, Price AH. Infusions of blood and other fluids via the bone marrow in traumatic shock and other forms of peripheral circulatory failure. *Ann Surg* 1941;114:1085-92
6. Elston JT, Jaynes RV, Kaump DH, Irwin WA. Intraosseous infusions in infants. *Am J Clin Pathol* 1947;17:143-50
7. Arbeiter HI, Greengard J. Tibial bone marrow infusion in infancy. *J Pediatr* 1944;25:1-12
8. Heinild S, Sondergaard T, Tudvad F. Bone marrow infusion in childhood. *J Pediatr* 1947;30:400-12
9. Tocantins LM, O'Neill JF, Jones HW. Infusions of blood and other fluids via the bone marrow. *JAMA* 1941;117:1229-34
10. Gimson JD. Bone marrow transfusion in infants and children. *Br Med J* 1944;1:748-9
11. Harte FA, Chalmers PC, Walsh RF, Danker PR, Sheikh FM. Intraosseous fluid administration: a parenteral alternative in pediatric resuscitation. *Anesth Analg* 1987;66:687-9
12. Engle WA. Intraosseous access for administration of medications in neonates. *Clin Perinatol* 2006;33:161-8
13. Rosetti VA, Thompson BM, Miller J, Mateer JR, Aprahamian C. Intraosseous infusion: an alternative route of pediatric intravascular access. *Ann Emerg Med* 1985;14:885-8
14. Orłowski JP. My kingdom for an intravenous line. *Am J Dis Child* 1984;138:803-6
15. Shoor PM, Berryhill RE, Benumof JL. Intraosseous infusion: pressure-flow relationship and pharmacokinetics. *J Trauma* 1979;19:772-4
16. Iserson KV, Criss E. Intraosseous infusion: a usable technique. *Am J Emerg Med* 1986;4:540-2
17. Prete MR, Hannan CJ, Burkle FM. Plasma atropine concentrations via intravenous, endotracheal, and intraosseous administration. *Am J Emerg Med* 1987;5:101-4
18. Papper EM. The bone marrow route for injecting fluid and drugs into the general circulation. *Anesthesiology* 1942;3:307-13
19. Macht DI. Studies on intraosseous injection of epinephrine. *Am J Physiol* 1943;138:269-72
20. Berg RA. Emergency infusion of catecholamines into bone marrow. *Am J Dis Child* 1984;138:810-1
21. Orłowski JP, Porembka DT, Gallagher JM, Lockrem JD, Van-Lente F. Comparison study of intraosseous, central intravenous and peripheral intravenous infusions of emergency drugs. *Am J Dis Child* 1990;144:112-7
22. Spivey WH, Lathers CM, Malone DR, Unger HD, Bhat S, McNamara RN, Schoffstall J, Tumer N. Comparison of intraosseous, central and peripheral routes of administration of sodium bicarbonate administration during CPR in pigs. *Ann Emerg Med* 1985;14:1135-40
23. Moore GP, Pace SA, Busby W. Comparison on intraosseous, intramuscular, and intravenous administration of succinylcholine. *Pediatr Emerg Care* 1989;5:209-10
24. Tobias JD, Nichols DG. Intraosseous succinylcholine for orotracheal intubation. *Pediatr Emerg Care* 1990;6:108-9
25. McNamara RM, Spivey WH, Unger HD, Malone DR. Emergency applications of intraosseous infusion. *J Emerg Med* 1987;5:97-101
26. Katan BS, Olshaker JS, Dickerson SE. Intraosseous infusion of muscle relaxants. *Am J Emerg Med* 1988;6:353-4
27. Selby IR, James MR. The intraosseous route for induction of anaesthesia. *Anaesthesia* 1993;48:982-4
28. Spivey WH, Unger HD, McNamara RM. Intraosseous diazepam suppression of pentylenetetrazol-induced epileptogenic activity in pigs. *Ann Emerg Med* 1987;16:156-9
29. Kentner R, Haas T, Gervais H, Hiller B, Dick W. Pharmacokinetics and pharmacodynamics of hydroxyethyl starch in hypovolemic pigs; a comparison of peripheral and intraosseous infusion. *Resuscitation* 1999;40:37-44
30. Stone MB, Teismann NA, Wang R. Ultrasonographic confirmation of intraosseous needle placement in an adult unembalmed cadaver model. *Ann Emerg Med* 2007;49:515-9
31. Calkins MD, Fitzgerald G, Bentley TB, Burris D. Intraosseous infusion devices: a comparison for potential use in special operations. *J Trauma* 2000;48:1068-74
32. Spriggs NM, White LJ, Martin SW, Brawley D, Chambers RM. Comparison of two intraosseous infusion techniques in an EMT training program. *Acad Emerg Med* 2000;7:1168
33. Brenner T, Bernhard M, Helm M, Doll S, Volkl A, Ganion N, Friedmann C, Sikinger M, Knapp J, Martin E, Gries A. Comparison of two intraosseous infusion systems for adult emergency medical use. *Resuscitation* 2008;78:314-9
34. Frascione RJ, Jensen JP, Kaye K, Salzman JG. Consecutive field trials using two different intraosseous devices. *Prehosp Emerg Care* 2007;11:164-71
35. Lake W, Emmerson AJB. Use of a butterfly as an intraosseous needle in an oedematous preterm infant. *Arch Dis Child Fetal Neonatal Ed* 2003;88:409-11
36. Tarrow AB, Turkel H, Thompson MS. Infusions via the bone marrow and biopsy of the bone and bone marrow. *Anesthesiology* 1952;13:501-9
37. Valverde A, Bienzle D, Smith DA, Dyson DH, Valliant AE. Intraosseous cannulation and drug administration for induction of anesthesia in chickens. *Vet Surg* 1993;22:240-4
38. Kamiloglu A, Atalan G, Kamiloglu NN. Comparison of intraosseous and intramuscular drug administration for induction of anaesthesia in domestic pigeons. *Res Vet Sci* 2008;85:171-5
39. Stewart FC, Kain ZN. Intraosseous infusion: elective use in pediatric anesthesia. *Anesth Analg* 1992;75:626-9
40. Boucek CD, El Magd KA. Alternative route transfusion for transplantation surgery in patients lacking accessible veins. *Anesth Analg* 2006;102:1591-2
41. Joshi G, Tobias JD. The use of intraosseous infusions in the operating room. *J Clin Anesth* 2008;20:469-73
42. Waisman M, Roffman M, Burzstein S, Heifetz M. Intraosseous regional anesthesia as an alternative to intravenous regional anesthesia. *J Trauma* 1995;39:1153-6
43. Fiser DH. Intraosseous infusion. *N Engl J Med* 1990;322:1579-81
44. Alam HB, Punzalan CM, Koustova E, Bowyer MW, Rhee P. Hypertonic saline: intraosseous infusion causes myonecrosis in a dehydrated swine model of uncontrolled hemorrhagic shock. *J Trauma* 2002;52:18-25
45. Rimer S, Westry JA, Rodriguez RL. Compartment syndrome in an infant following emergency intraosseous infusion. *Clin Pediatr* 1988;27:259-60
46. Hasan MY, Kissoon N, Khan TM, Saldajeno V, Goldstein J, Murphy SP. Intraosseous infusion and pulmonary fat embolism. *Pediatr Crit Care Med* 2001;2:133-8
47. Orłowski JP, Julius CJ, Petras RE, Porembka DT, Gallagher JM. The safety of intraosseous infusions: risks of fat and bone marrow emboli to the lungs. *Ann Emerg Med* 1989;18:1062-7
48. Waisman M, Waisman D. Bone marrow infusion in adults. *J Trauma* 1997;42:288-93
49. Bowley DM, Loveland J, Pitcher GJ. Tibial fracture as a complication of intraosseous infusion during pediatric resuscitation. *J Trauma* 2003;55:786-7
50. Melker RJ, Miller G, Gearen P, Mollita L. Complications of intraosseous infusion. *Ann Emerg Med* 1990;19:731-2
51. Fiser RT, Walker WM, Seibert JJ, McCarthy R, Fiser DH. Tibial length following intraosseous infusion. *Pediatr Emerg Care* 1997;13:186-8

52. Haas NA. Clinical review: vascular access for fluid infusion in children. *Crit Care* 2004;8:478–84
53. Reynolds LM, Lau M, Brown R, Luks A, Fisher DM. Intramuscular rocuronium in infants and children: dose-ranging and tracheal intubating conditions. *Anesthesiology* 1996;85:231–9
54. Mamie C, Habre W, Delhumeau C, Argiroffo CB, Morabia A. Incidence and risk factors of perioperative respiratory adverse events in children undergoing elective surgery. *Pediatr Anesth* 2004;14:218–24
55. Bohn D. Intraosseous vascular access: from the archives to the ABC. *Crit Care Med* 1999;27:1053–4
56. Atkins DL, Chameides L, Fallat ME, Hazinski MF, Phillips B, Quan L, Schleien CL, Terndrup TE, Tibballs J, Zideman DA. American Heart Association; International Liaison Committee on Resuscitation. Resuscitation science of pediatrics. *Ann Emerg Med* 2001;37:S41–8
57. The International Liaison Committee on Resuscitation (ILCOR) consensus on science with treatment recommendations for pediatric and neonatal patients: pediatric basic and advanced life support. *Pediatrics* 2006;117:e955–77